



Colon

HPA007875

Male, age 14

Colon (T-67000)

Normal tissue, NOS (M-00100)

Patient id: 1990

Endothelial cells

Staining: **Not detected**

Intensity: **Negative**

Quantity: **None**

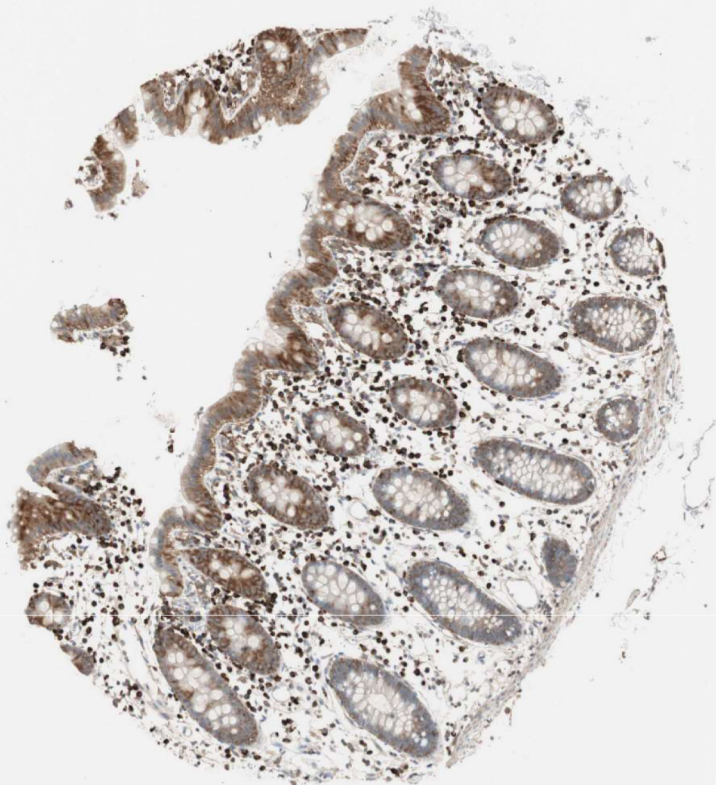
Glandular cells

Staining: **High**

Intensity: **Strong**

Quantity: **75%-25%**

Location: **Cytoplasmic/
membranous**





Rectum

HPA007875

Female, age 46

Rectum (T-68000)

Normal tissue, NOS (M-00100)

Patient id: 1876

Glandular cells

Staining: **High**

Intensity: **Strong**

Quantity: **75%-25%**

Location: **Cytoplasmic/
membranous**





Colorectal cancer

HPA007875

Male, age 45

Colon (T-67000)

Adenocarcinoma, NOS

(M-81403)

Patient id: 693

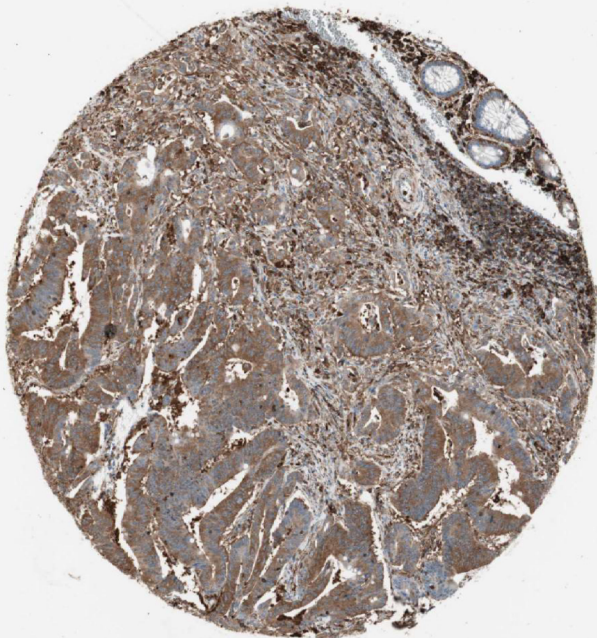
Tumor cells

Staining: **High**

Intensity: **Strong**

Quantity: **>75%**

Location: **Cytoplasmic/
membranous**





Colorectal cancer

HPA007875

Male, age 55

Rectum (T-68000)

Adenocarcinoma, NOS
(M-81403)

Patient id: 349

Tumor cells

Staining: **High**

Intensity: **Strong**

Quantity: **>75%**

Location: **Cytoplasmic/
membranous**

