

## Endometrioid carcinoma

## Clear cell carcinoma

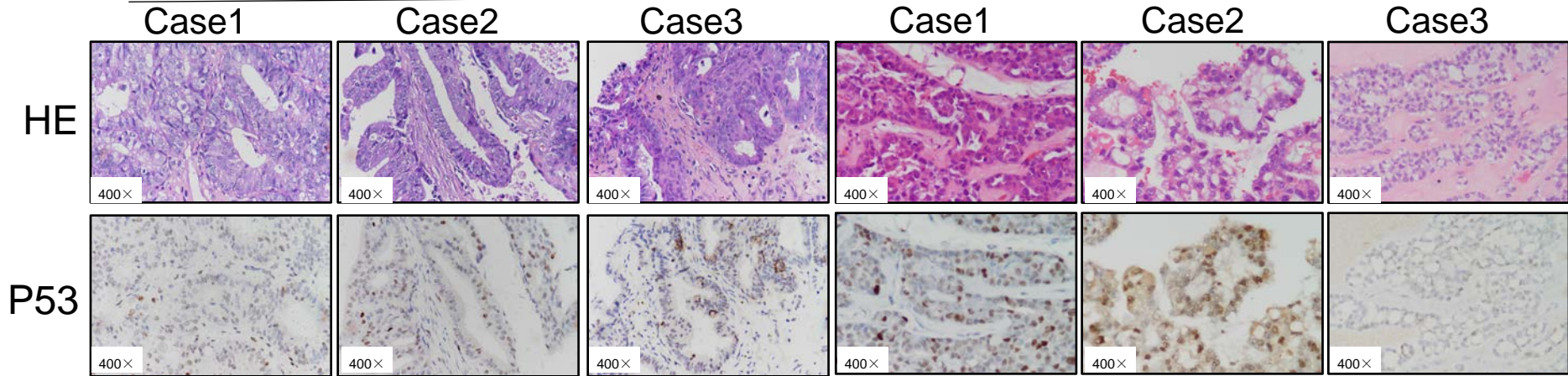


Figure S1. Immunohistochemical staining of p53 in endometrioid carcinoma tissues and clear cell carcinoma tissues.